PRIMEPHYSIO

TRAINING FOR PHYSIOTHERAPISTS

PRIMEPHYIO TRAINING UK

Advanced Manual Therapy Program

Mahmoud Saad

OMTA

2006-2018

www.primephysio.com

www.PRIMEPHYSIO.com 2006-2018

8000 physiotherapists and Medical doctors

UK-Egypt-Oman-Kuwait-Lebanon –Jordan-KSA-Qatar-Malta-Sweden-Sudan-Dubai

Introducing concepts
Holistic Management
Changing beliefs

PRIMEPHYSIO

TRAINING FOR PHYSIOTHERAPISTS

PRIMEPHYSIO

TRAINING FOR PHYSIOTHERAPISTS

Scope of Practice

- Emphasis on Quality Evidence.
  Active Learning
- experienced tutors with strong clinical and academic background.
- Affiliate with teaching and clinical organizations
- Physiotherapy courses at basic expenses cost in developing countries
- Accreditation service
- Free access to learning activities
  free online courses.

Sheffield Hallam University

Program Tutor:

Mahmoud Saad

Associate Senior Lecturer. Sheffield Hallam University SHU-UK.
Fellow Higher Education academy.UK
Certified McKenzie Therapist-Chair MIE 2010-2013
Clinical specialist - National Health Service NHS.UK
Chartered Society Physiotherapy MCSP.
Certified Medical Taping Tutor.
PRIMEPHYSIO. Founder.
Certified Manual therapist. UK. IFOPMT
Chairperson . Orthopedic Manual therapy Egypt OMTAE

Best modern university in the north of England 2016…

- Undergraduate Program
- Advanced Msc Physiotherapy
  - F2F
  - Distance Learning
- MSc in Manual Therapy
- PHD Program
- Professional doctorate program

Program Structure

- **Block 1:**

Patient demonstration

•Cervical spine, shoulder and thoracic spine differentiation and management.
•Lumbar spine, SIJ and Hip differentiation and management.
•Chronic scenarios where central sensitisation and yellow flags are evident.
•Acute Cases where we can produce within session changes.

Block 2:

Practical applications

- All body joints mobilisations: Shoulder-Elbow-Wrist-Hip-Knee-SIJ-Ankle-cervical/thoracic and lumbar mobilisation (Loaded/unloaded-with/without movement)
- Thoracic and lumbar spine manipulation: Variety of evidence based methods
- Exercise prescription to optimise motor control for upper quadrant and lower quadrant

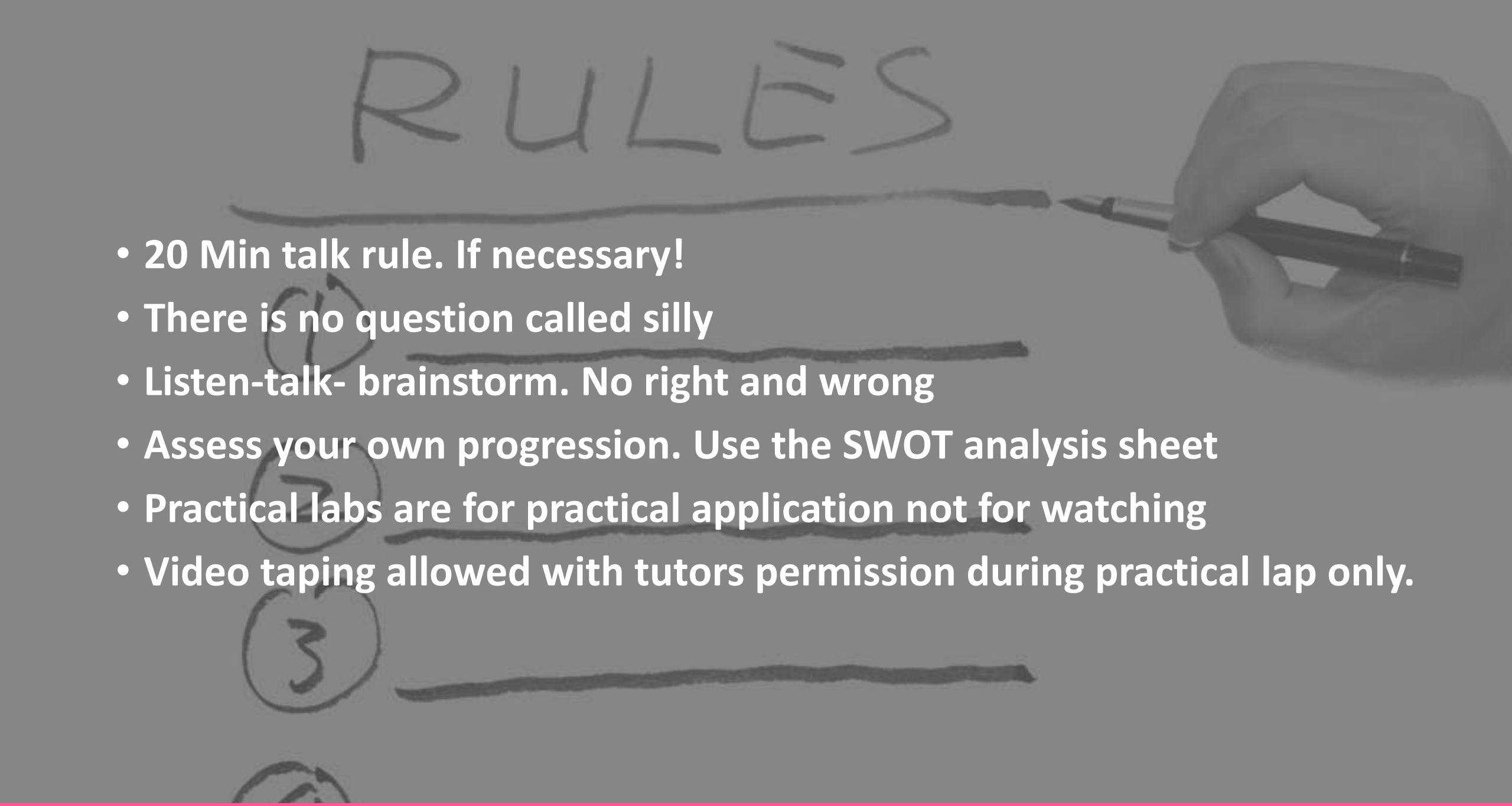

- 20 Min talk rule. If necessary!
- There is no question called silly
- Listen-talk- brainstorm. No right and wrong
- Assess your own progression. Use the SWOT analysis sheet
- Practical labs are for practical application not for watching
- Video taping allowed with tutors permission during practical lap only.

Your objectives !



Cervicogenic Headaches (CGHs)

- Pain referred to the head from the cervical spine. Bogduk 2009

- Pain that radiates from the neck to the fronto-temporal region and reproduced with neck movements. International Headache society

- Caused by a disorder of the cervical spine and its component bony, disc and/or soft tissue elements, usually but not invariably accompanied by neck pain. International Headache society

- A secondary headaches result from another source including inflammation or head and neck injuries. Dr. Ottar Sjaastad,1983

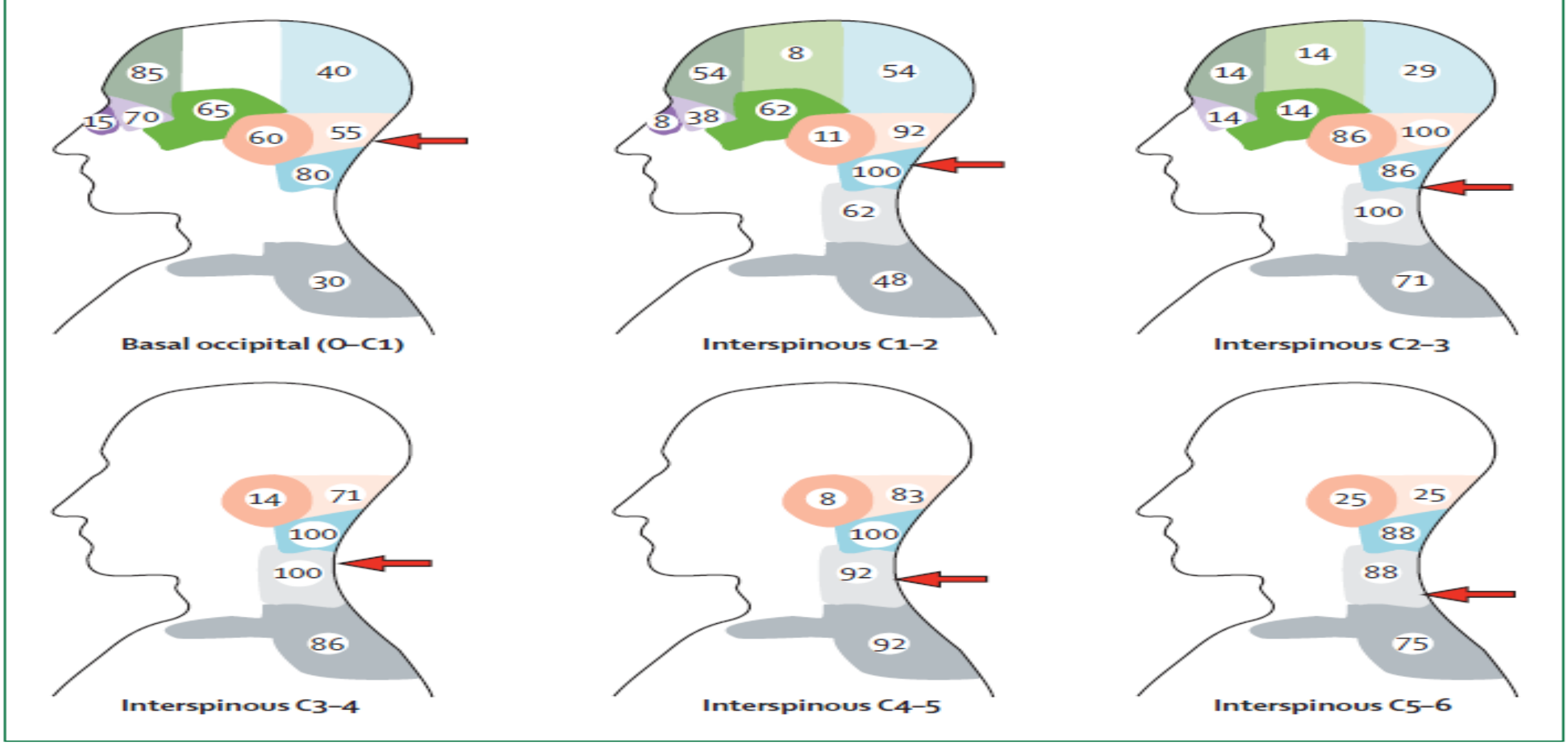

Figure 2: **Referred pain patterns after noxious stimulation of basal occipital periosteum and interspinous muscles at C1–2, C2–3, C3–4, C4–5, and C5–6**

The more cephalad the site of stimulation, the more likely that pain is referred to distant regions of the head. The numbers indicate the percentage of individuals who reported pain in the area shown after stimulation at each segmental level. The arrows indicate the approximate site of stimulation. Adapted from Campbell and Parsons, with permission from Lippincott Williams & Wilkins.[10]

Conclusions from the Literature

- (CGHs) accounting for 15–20% of all chronic and recurrent headaches.
- (CGHs) referred to as occipital headaches, are the most common persistent symptom following cervical neck/spine trauma such as a whiplash injury.
- CGH patients frequently do not respond to medications.

Conclusions from the Literature

- **Diagnostics**

- Imaging findings in the upper cervical spine are common in patients without headache; they are suggestive but not firm evidence of causation.

Types and sub classifications of headaches

Primary headaches :

Vascular origin (cluster and migraine headaches)

Muscular origin (tension-type headaches)

Secondary headaches :

Headache or facial pain attributed to disorder of the cranium, neck, eyes, ears, nose, sinuses, teeth, mouth or other **facial** or cervical structure

(CGHs) Common Symptoms

Pain	Unilateral or Bilateral
	Affecting the head or face but has most commonly affected the occipital region, frontal region or retro-orbital region
	Associated with suboccipital neck pain
Others	Ipsilateral arm discomfort
	Dizziness, nausea, lightheadedness
	Inability to concentrate, retro-ocular pain, visual disturbances

Pathophysiology- Bogduk (2006)

- Upper cervical facets
- Upper cervical muscles
- C2-3 intervertebral disc
- Vertebral and internal carotid arteries
- Dura mater of the upper spinal cord
- Posterior cranial fossa

Diagnostic criteria/ DD

1 Unilateral headache without side-shift

2 Symptoms and signs of neck involvement: pain triggered by neck movement or sustained awkward posture and/or external pressure of the posterior neck or occipital region; ipsilateral neck, shoulder, and arm pain; reduced range of motion

3 Pain episodes of varying duration or fluctuating continuous pain

4 Moderate, non-excruciating pain, usually of a non-throbbing nature

Diagnostic criteria/DD

5 Pain starting in the neck, spreading to oculo-fronto-temporal areas

6 Anaesthetic blockades abolish the pain transiently provided complete anaesthesia is obtained, or occurrence of sustained neck trauma shortly before onset

7 Various attack-related events: autonomic symptoms and signs, nausea, vomiting, ipsilateral oedema and flushing in the peri-ocular area, dizziness, photophobia, phonophobia, or blurred vision in the ipsilateral eye

Table I. Criteria for cervicogenic headache.

I	Unilaterality without sideshift
IIa1	Pain triggered by neck movement and/or sustained awkward position
IIa2	Pain elicited by external pressure over the ipsilateral upper, posterior neck region or occipital region
IIb	Ipsilateral non-radicular neck, shoulder, and arm pain
IIc	Reduced range of motion in the cervical spine
III	Non-clustering pain episodes
IV	Pain episodes of varying duration or fluctuating, continuous pain
V	Moderate, non-excruciating pain, usually of a non-throbbing nature
VI	Pain starting in the neck, eventually spreading to oculo-fronto-temporal areas where the maximum pain is usually located
VII	Anaesthetic blockades of the major occipital nerve; C2 root or other appropriate structures on the symptomatic side abolish the pain transiently, provided anaesthesia is obtained
VIII	Female sex
IX	Head and/or neck trauma
Xa	Nausea
Xb	Vomiting
Xc	Ipsilateral edema, and - less frequently - flushing, mostly in the periocular area
XI	Dizziness
XII	Phono- and photophobia
XIII	Ipsilateral "blurred vision"
XIV	Difficulties on swallowing

Grade	Criteria
A	Pain referred from a source in the neck and felt in one or more regions of the head and/or face, fulfilling criteria C and D
B	Clinical laboratory and/or imaging evidence of a disorder or lesion within the cervical spine or soft tissues of the neck known to be, or generally accepted as a valid cause of headache
C	Evidence that the pain can be attributed to the neck disorder or lesion based on at least one of the following: 1) evidence of clinical signs that implicate a source of pain in the neck, or abolition of headache after diagnostic blockade of a cervical structure or its nerve supply with placebo or adequate controls
D	Pain resolves within 3 months after successful treatment of the causative disorder or lesion

Turning Examination into treatment

Smile is analgesic (Louro & Sousa, 2014).	Challenging the concept not the person. (Mosley 2017)	Introduce new concept (Mosley 2017)	Focus on abilities not disabilities.
Pain Vs problem	Sign the contract.. Driver seat must be yours.	Professionalism … Positive , Caring attitude.	The white shirt vs polo shirt – student vs senior – Lada Vs mercedes

A good examination is the key to successful treatment.

Aim of examination

10 seconds rule

What is the aim of my examination today?
Rule out red flags
Set outcome measures
Identify area/s of symptoms
Identify source/s of symptoms
Pick treatment tools
Send few message across to the patient

Red Flags

- Headaches that are getting worse over time
- Sudden onset of severe headache
- Headaches associated with high fever, stiff neck, or rash
- Onset of headache after head injury
- Problems with vision or profound dizziness

Case Study

Manual Therapy Interventions

Because CGH is related to cervical joint dysfunction, most studies on CGH treatment have focused on joint mobilization and manipulation.

Cervical manipulation and mobilization, along with exercise, were the most effective conservative interventions for decreasing CGH intensity, frequency, and neck pain, which is consistent with the literature.

OMTA

PRIMEPHYSIO
TRAINING FOR PHYSIOTHERAPISTS

Manipulation

- Upper cervical spinal manipulative therapy (SMT) is effective for CGH (better outcomes compared to no treatment)
- Both mobilization and manipulation are effective for treatment of patients with cervical pain, although manipulation appears superior to mobilization in the short term, O'Leary, S., et al. 2007
- Patients with neck pain with or without headache have more short term relief when manipulation is combined with exercise as compared to exercise alone, Miller, J., et al. 2010

Mobilization

- An explanation for improvement of the subjects' headaches after treatment may be that cervical headaches stem from degenerative changes in the facet joints.
- Spinal mobilization for upper cervical vertebrae C1, 2, 3 within their normal range demonstrated clinical improvement in headache pain intensity, frequency and duration of headache pain.
- The neck range of motion in flexion, extension, rotation, lateral flexion for patients with CGH significantly increased after upper cervical mobilization.

Mobilization with movement (MWM) NAGs and SNAGs

Brian Mulligan

- C1-C2 Self-SNAG decreased headache index scores.
- Headache SNAG technique is more effective as compared to reverse headache SNAG to treat Cervicogenic headache.

Tractions, SNAGs and self-SNAGs

SNAG at C2

Reverse SNAG at C2

Rotatory SNAG C1-C2

Traction of upper cervical spine

Grip traction

Self-SNAG at C2

Reverse self-SNAG

Self-SNAG for C1-C2 rotation

Muscle Stretching

- SCM
- Upper trapezius
- Levator
- Scalenes
- Suboccipitals
- Pectoralis minor
- Pectoralis major

The post-isometric relaxation (PIR) technique

(First passively lengthening the muscle, then having the patient lightly contract 10-20% of maximum against resistance for 5 seconds passively before exhaling and relaxing the muscle and repeated. The clinician then takes up the slack within the muscle and repeats the technique 3 to 5 times)

Therapeutic Exercise

- Postural awareness.
- Muscle balance.
- Breathing.
- Exercise for activating the deep neck flexors.
- Improve upper quarter strength.
- Sensorimotor training.

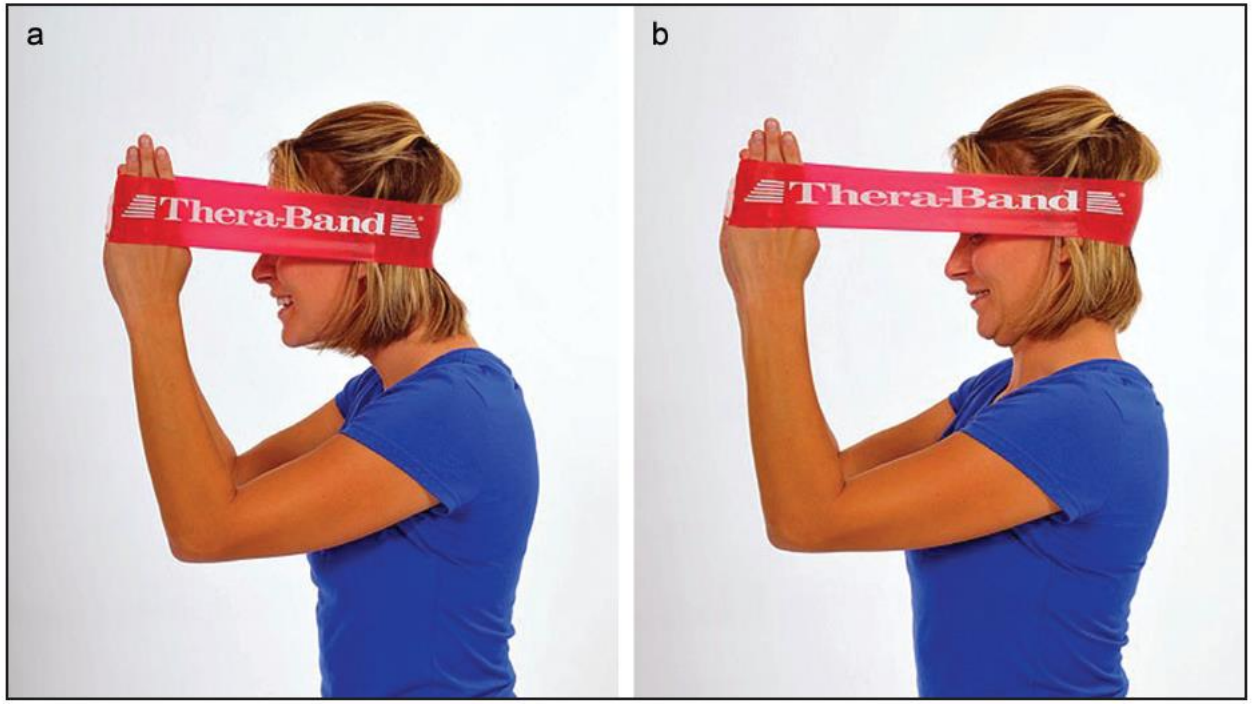

Figure 6a-b: *Craniocervical flexion against elastic band loop. Begin with cervical spine in protraction (a). Maintain hand position while retracting against the tension in the band (b). (Used with permission of The Hygenic Corporation).*

Figure 5. *Dynamic Cervical Extension Exercise. The patient performs a 'hip hinge', stabilizing the cervical spine against the resistance in 4 directions (Used with permission of The Hygenic corporation).*

OMTA

PRIMEPHYSIO
TRAINING FOR PHYSIOTHERAPISTS

PRACTICAL LAB

PAIVM/PPIAVM /MWM/SNAGS

- Cervical Spine

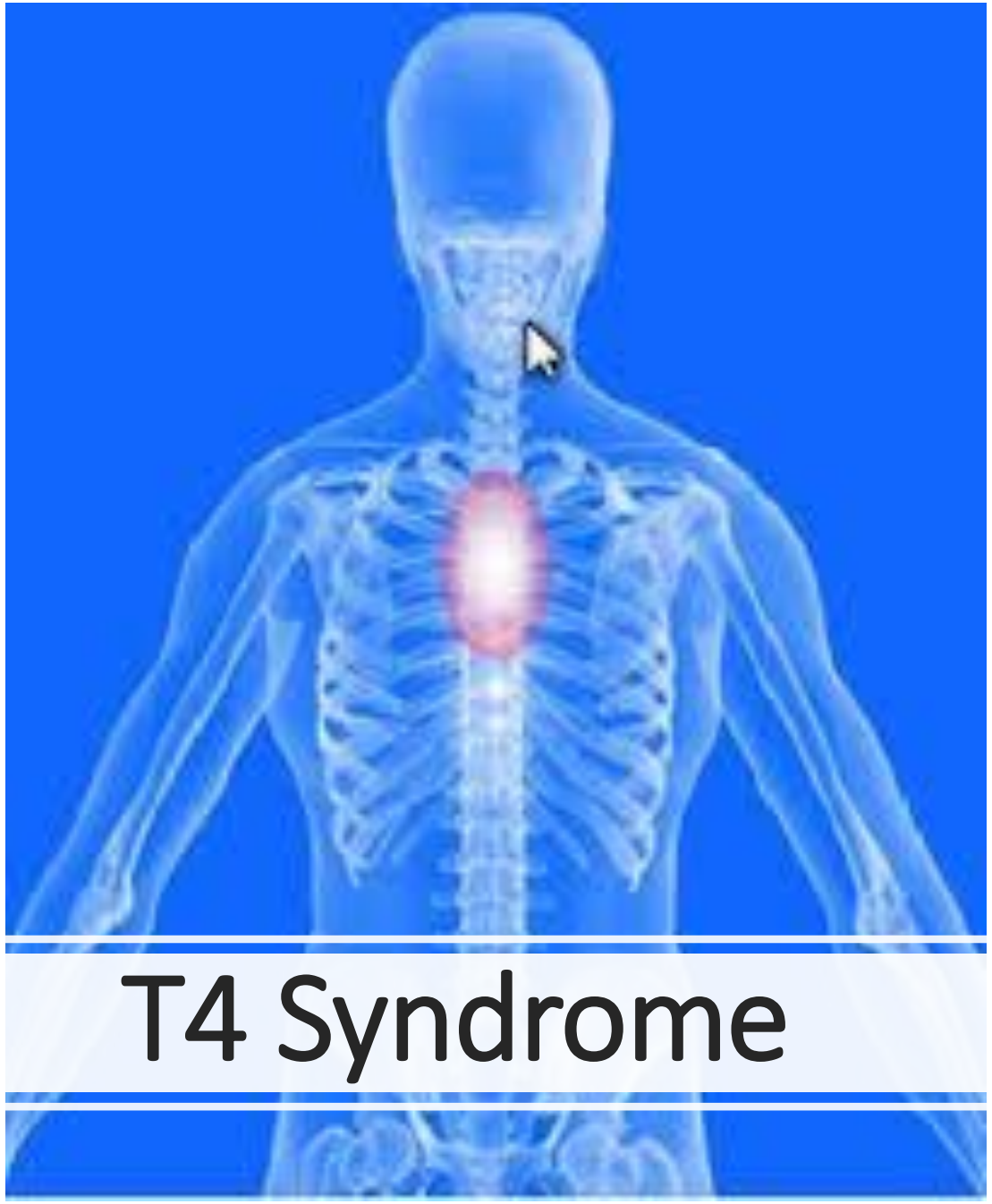

T4 Syndrome

T4 SYNDROME!

- A clinical pattern that involves upper extremity paraesthesia and pain with or without symptoms into the neck and/or head.

(Maitland, 1986)

(Hengeveld and Banks, 2013).

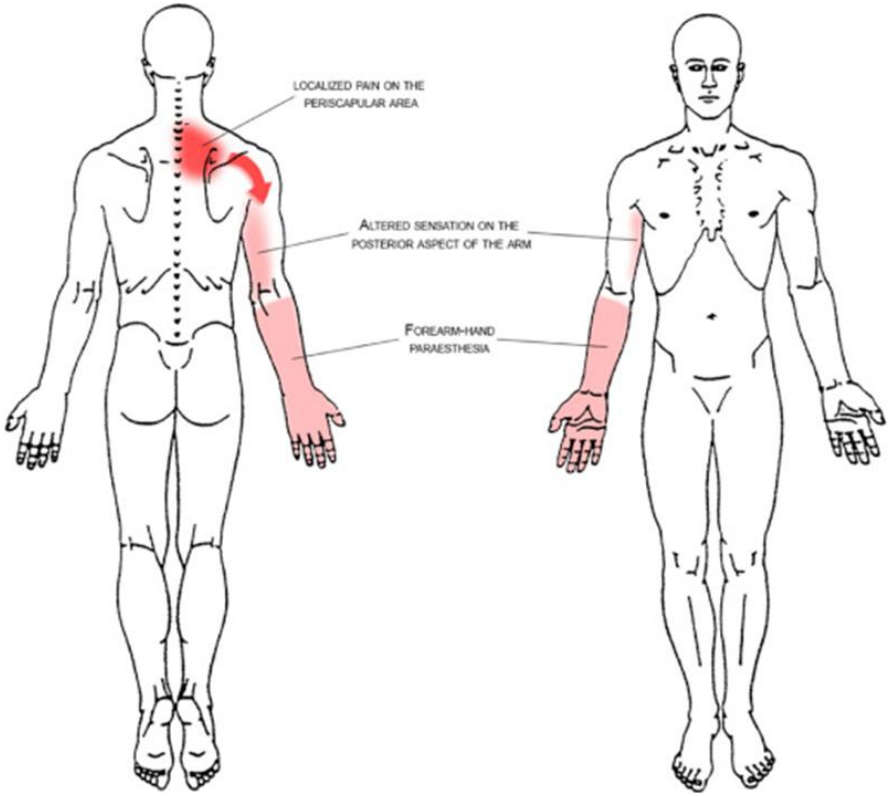

SYMPTOMS

- Upper extremity (UE) paresthesia and pain with or without symptoms into the neck, upper back and/or head.

(Hengeveld and Banks, 2013)

- Symptoms have been reported as bilateral or unilateral.

(Conroy and Schneiders, 2005)

- Transient paresthesia in all-five-digits, whole-hand or forearm-hand (glove-like distribution).

- Associated or not with non-dermatomal pain in the arm and/or forearm.
- Referred pain and/or stiffness into the neck or scapular regions.
- Abnormal sensory, sudomotor and/or trophic findings in the UE.

(Mellick and Mellick, 2006, Evans, 1997 and DeFranca and Levine, 1995)

- Decreases in grip strength with a handheld dynamometer.
- SNS pain mechanism commonly presents with sudomotor changes (cold peripheries and increased sweating) and vasomotor changes (blanching of the skin).

(Siddall and Cousins, 1997).

Reference	Type of Study	Sackett Level of Evidence	Sensory Changes	Pain Characteristics	Neuromusculoskeletal System
DeFranca[5]	Case series	4—case series	Patient 1: Bilateral hand paresthesia/anesthesia. Entire LUE vs right hand and wrist Patient 2: Bilateral symmetrical hand numbness and paresthesia	Patient 1: Tenderness to palpation at T4-5 Patient 2: Tenderness to palpation T3-4 Sensitivity to skin rolling, dull occipital headache	Patient 1: Hypomobile T4-5, shortened scalene and pectoral muscles Patient 2: Kyphotic, rounded shoulders, T3-T4 hypomobile
Evans[3]	Focus piece	5—expert opinion	Glove paresthesia, hands feel hot, cold, heavy, or swollen.	Nondermatomal pain in arms or forearms Description of pain is bursting or like a tight band Pain may be in thorax, cervical spine, and is not affected by movement of either UE or spine	Tenderness to palpation at hypomobile segment, often with forward head posture, and kyphosis
Mellick[6]	Case series	4—case series	Patient 1: Bilateral hand paresthesia Reduced sensitivity to light touch, pinprick, and proprioception in right hand Patient 2: Cramping, hypoesthesia, paresthesias, and dysthesias in bilateral UE Description is hands are cold and falling asleep	Patient 1: Upper back and neck pain, pain with movement, allodynia, occipital headache, and right eye pain Patient 2: Shoulder myofascial trigger points, thoracic spine hyperalgesia Tenderness at skull base and muscle contraction HA, pain over TMJ	Patient 1: Bilateral grasp weakness, limited and painful neck ROM Patient 2: Bilateral grasp weakness, decreased cervical spine ROM; flexion was most limited and painful
Conroy[7]	Case report	5—expert opinion	Paresthesia in both palms Left more intense than the right Paresthesia also reported across face	Pain in both shoulders and down arms and associated headache Pain reported as 8/10	Increased lumbar and cervical lordosis and angulation at CTJ Decreased thoracic kyphosis; taught upper trapezius muscles, reduced cervical ROM and painful and hypomobile T4
Feldman[8]	Case report/ abstract only	5—expert opinion	Constant bilateral pain and paresthesias in UE	Constant UE pain beginning at 6/10	N/A
McGuckin[2]	Textbook entry	5—expert opinion	Unilateral or bilateral UE paresthesia in glove distribution Symmetrical or asymmetrical	Neck, upper thoracic, and scapular pain Generalized headache in “helmet" pattern	Painful and hypomobile accessory motion of the spine
Maitland[1]	Textbook entry	5—expert opinion	Referral of dull feeling or paresthesia into the head or hand	Thoracic or scapular pain, or headache	Painful and limited cervical flexion and tenderness to palpation of thoracic segment
Olson[20]	Textbook entry	5—expert opinion	UE paresthesia	UE pain with symptoms into the neck or head	Limited and painful thoracic segments T3-T5
Jowsey[19]	Randomized placebo-controlled trial	1B—randomized controlled trial with narrow confidence interval	Glove distribution of paresthesia	N/A	N/A
Geerse[13]	Case report	5—expert opinion	Deep sensation of heaviness and tiredness of bilateral LE with right leg worse than left	Pain at the thoracolumbar junction described as deep and nagging	Limited flat-back posture, extension and right rotation Sympathetic slump limited and provoked LBP PAIVMS of thoracic spine revealed loss of ROM tenderness to PA glides at T10 PPIVMS—loss of right rotation at L3 and L4
Bogduk[21]	Focus piece	5—expert opinion	UE referred symptoms		Hypomobility of T4 segment

PATHO-MECHANISMS

- Altered activity in the sympathetic nervous system (SNS) has been suggested as a possible mechanism linking the thoracic spine to the T4 syndrome referral pattern.

(Jowsey and Perry, 2010)

- Noxious stimuli, that mediate nociceptive information to the dorsal horn and spinal medulla which seems to result in heightened sudomotor and vasomotor tone.

(DeFranca and Levine 1995)

PATHO-MECHANISMS

- Referred pain with sensory and autonomic features could result from a combination of sensory processing changes in the dorsal horn.

  (Mense, 2008)

- Formation of myofascial trigger points (MFTPs).

  (Bron and Dommerholt, 2012).

- The presence of a hypomobile thoracic segment may indicate involvement of a synovial joint structure.

  (Bogduk,1986)

Physical Examination

- Cervical x-rays.
- Nerve conduction testing.
- Electromyographic analysis.
- Out thoracic outlet syndrome.
- Carpal tunnel syndrome.
- Lower cervical nerve root lesions.
- Cardiac issues.

Postural observation:

- Increased lumbar and cervical lordosis.
- Decreased upper thoracic kyphosis and flexed cervico-thoracic junction.

Palpation

- Tenderness

Mobility

- The cervical and upper thoracic spine, GHJ.
- Hypo mobility

Case Study

Managements & Outcomes

- Soft tissue treatment.

- A supine upper thoracic HVLAT manipulation.

(Dunning et al., 2012)

- T4 paraspinal injections.

(Gary et al.,2006)

- Mobilisation has shown to be mildly effective in achieving a hypoalgesic, motor, and sympathoexcitatory effect.
- (Conroy and Schneiders, 2005, Mellick and Mellick, 2006, Evans, 1997 and DeFranca and Levine, 1995)

- A grade III postero-anterior rotatory mobilisation technique applied to the T4 vertebrae.

(Pete Jowsey , Jo Perry, 2010)

Author	Intervention	Outcomes
DeFranca[5]	Patient 1: Thrust manipulation followed by postural, stretching, and strengthening exercises Patient 2: PA mobilization and thrust manipulation of the hypomobile segment, followed by flexibility exercises for the pectoral muscles and upper back strengthening	Patient 1: “Dramatic relief" after a single manipulation, continued relief after 6 months Patient 2: After 3 treatments, night symptoms resolved After 6 additional treatments over 2 weeks, headache resolved At 3- and 6-month follow-ups, patient remained asymptomatic
Mellick[6]	Patient 1: Series of 3 bilateral paraspinal injections with addition of Neurontin 3 times/day, followed by 3 cervical epidural injections 6 months later Patient 2: Series of 3 bilateral paraspinal injections followed by osteopathic spinal mobilization and physical therapy; also given Neurontin 3 times/day	Patient 1: After paraspinal injections—immediate but transient relief of paresthesia, improved sensory testing, immediate improvement in grip strength After epidural injections—improvement an relief of UE symptoms Patient 2: Immediate but transient relief of UE symptoms after paraspinal injections, full resolution after mobilization techniques and physical therapy
Conroy[7]	Grade II central PA mobilization, postural education and correction, Pilates exercise program	Improvement of cervical range of motion and resolution of UE symptoms Not available for 6-month follow-up
Feldman[8]	Thrust manipulation and myofascial interventions	6/10 pain reduced to 0/10 with increased ability to participate in rest, work, and school
Geerse[13]	Unilateral grade III PA mobilization on hypomobile segment, education on avoiding postures at work, self-mobility with thoracic rotation and lumbar extension	Heaviness and night symptoms decreased after third treatment (16 days) Improved accessory motion and normalization of sympathetic slump test Remained asymptomatic after 3 months
Maitland[1]	PA glides to the hypomobile spinal segments after an unsuccessful course of traction	Resolution of symptoms with mild recurrence
Olson[20]	Manipulation (thrust or nonthrust) and postural and thoracic mobility exercises	After manipulation, symptoms subside and improvements in ULND testing is noted Usually see improved mobility
McGuckin[2]	Localized segmental mobilization and/or manipulation, posture correction, patient education	None
Bogduk[21]	Suggested manipulation of the T4 segment	None

PRACTICAL LAB

PAIVM/PPIAVM /MWM/Mnipulation

- Thoracic Spine

Reference list

- Bogduk, N. and Govind, J., 2009. Cervicogenic headache: an assessment of the evidence on clinical diagnosis, invasive tests, and treatment. *The Lancet Neurology*, *8*(10), pp.959-968.
- Page, P., 2011. Cervicogenic headaches: an evidence-led approach to clinical management. *International journal of sports physical therapy*, *6*(3), p.254.
- Racicki, S., Gerwin, S., DiClaudio, S., Reinmann, S. and Donaldson, M., 2013. Conservative physical therapy management for the treatment of cervicogenic headache: a systematic review. *Journal of manual & manipulative therapy*, *21*(2), pp.113-124.
- Yadla, M.D., Gehret, J., Campbell, P., Mandel, S., Ratliff, M.D. and John, K., 2010. A pain in the neck: review of cervicogenic headache and associated disorders. *JHN Journal*, *5*(1), p.6.
- Steiner T, Paemeliere K, Jensen R et al. European principles of management of common headache disorders in primary care. J Headache Pain 2007; 8 (Suppl. 1): S3–47.
- Schwartz BS, Stewart WF, Lipton RB. Lost workdays and decreased work effectiveness associated with headache in the workplace. J Occup Environ Med 1997;39:320–7.
- McDermaid, C.S., Hagino, C. and Vernon, H., 1999. Systematic review of randomized clinical trials of complementary/alternative therapies in the treatment of tension-type and cervicogenic headache. *Complementary therapies in Medicine*, *7*(3), pp.142-155.
- Antonaci, F., Ghirmai, S., Bono, G., Sandrini, G. and Nappi, G., 2001. Cervicogenic headache: evaluation of the original diagnostic criteria. *Cephalalgia*, *21*(5), pp.573-583.
- Dimitriadis, Z., The effectiveness of Mulligan techniques on cervicogenic headache: clinical applications and research evidence.

Reference list

- Sjaastad, O. and Fredriksen, T.A., 2000. Cervicogenic headache: criteria, classification and epidemiology. *Clinical and experimental rheumatology*, *18*(2; SUPP/19), pp.S-3.
- Rasul, H.N.U., Dustagir, A. and Malik, A.N., Role of Mobilization to Improve Cervicogenic Headache.
- Schoensee, S.K., Jensen, G., Nicholson, G., Gossman, M. and Katholi, C., 1995. The effect of mobilization on cervical headaches. *Journal of Orthopaedic & Sports Physical Therapy*, *21*(4), pp.184-196.
- José, P. and Perry, J., 2010. Sympathetic nervous system effects in the hands following a grade III postero-anterior rotatory mobilisation technique applied to T4: a randomised, placebo-controlled trial. *Manual therapy*, *15*(3), pp.248-253.
- McGuckin, N., 1986. The T4 syndrome. In *Modern manual therapy of the vertebral column* (pp. 370-376). Churchill Livingstone, Edinburgh.
- Mellick, G.A. and Mellick, L.B., 2006. Clinical presentation, quantitative sensory testing, and therapy of 2 patients with fourth thoracic syndrome. *Journal of manipulative and physiological therapeutics*, *29*(5), pp.403-408.
- Aiken, D.L. and Vaughn, D., 2013. The use of functional and traditional mobilization interventions in a patient with chronic thoracic pain: a case report. *Journal of Manual & Manipulative Therapy*, *21*(3), pp.134-141.
- DeFranca, G.G. and Levine, L.J., 1995. The T4 syndrome. *Journal of manipulative and physiological therapeutics*, *18*(1), pp.34-37.
- Menck, J.Y., Requejo, S.M. and Kulig, K., 2000. Thoracic spine dysfunction in upper extremity complex regional pain syndrome type I. *Journal of Orthopaedic & Sports Physical Therapy*, *30*(7), pp.401-409.